

Chapter 01: Anatomy and Physiology
Aehlert: ECGs Made Easy, 6th Edition

MULTIPLE CHOICE

1. The apex of the heart is formed by the _____.
 - a. tip of the left ventricle
 - b. tip of the right atrium
 - c. right atrium and right ventricle
 - d. left atrium and left ventricle

ANS: A

The heart's apex, or lower portion, is formed by the tip of the left ventricle. The apex lies just above the diaphragm, between the fifth and sixth ribs, in the midclavicular line.

OBJ: Identify the surfaces of the heart.

2. The left atrium receives blood from the _____.
 - a. pulmonary veins
 - b. aorta
 - c. pulmonary arteries
 - d. inferior vena cava

ANS: A

The left atrium receives freshly oxygenated blood from the lungs via the right and left pulmonary veins.

OBJ: Identify and describe the chambers of the heart and the vessels that enter or leave each.

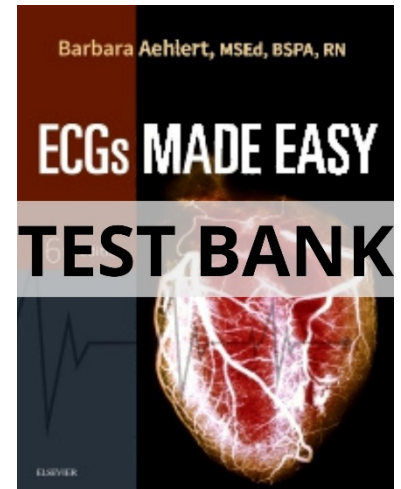
3. The anterior surface of the heart consists primarily of the _____.
 - a. left atrium
 - b. right atrium
 - c. left ventricle
 - d. right ventricle

ANS: D

The front (anterior) surface of the heart lies behind the sternum and costal cartilages. It is formed by portions of the right atrium and the left and right ventricles. However, because the heart is tilted slightly toward the left in the chest, the right ventricle is the area of the heart that lies most directly behind the sternum.

OBJ: Identify the surfaces of the heart.

4. Blood pressure is determined by _____ multiplied by _____.
 - a. stroke volume; heart rate
 - b. heart rate; cardiac output
 - c. cardiac output; peripheral vascular resistance
 - d. stroke volume; peripheral vascular resistance



Test Bank For ECGs Made Easy 6th Edition Barbara Aehlert

ANS: C

Blood pressure is equal to cardiac output multiplied by peripheral vascular resistance.

OBJ: Identify and explain the components of blood pressure and cardiac output.

5. The right atrium receives venous blood from the head, neck, and thorax via the _____, from the remainder of the body via the _____, and from the heart via the _____.
- coronary sinus; superior vena cava; inferior vena cava
 - superior vena cava; coronary sinus; inferior vena cava
 - inferior vena cava; superior vena cava; coronary sinus
 - superior vena cava; inferior vena cava; coronary sinus

ANS: D

The right atrium receives blood low in oxygen from the superior vena cava, which carries blood from the head and upper extremities; the inferior vena cava, which carries blood from the lower body; and the coronary sinus, which is the largest vein that drains the heart.

OBJ: Identify and describe the chambers of the heart and the vessels that enter or leave each.

6. The heart is divided into _____ chambers but functions as a _____-sided pump.
- two; four
 - three; two
 - four; two
 - four; three

ANS: C

The heart has four chambers: two atria and two ventricles. The right and left sides of the heart are separated by an internal wall of connective tissue called a *septum*. The interatrial septum separates the right and left atria. The interventricular septum separates the right and left ventricles. The septa separate the heart into two functional pumps. The right atrium and right ventricle make up one pump. The left atrium and left ventricle make up the other.

OBJ: Identify and describe the chambers of the heart and the vessels that enter or leave each.

7. Stimulation of alpha1 receptors results in _____.
- increased heart rate
 - peripheral vasoconstriction
 - constriction of bronchial smooth muscle
 - increased force of myocardial contraction

ANS: B

Alpha1 receptors are found in the eyes, blood vessels, bladder, and male reproductive organs. Stimulation of alpha1 receptor sites results in constriction.

OBJ: Compare and contrast the effects of sympathetic and parasympathetic stimulation of the heart.

8. Which side of the heart is a low-pressure system that pumps venous blood to the lungs?
- Left
 - Right

ANS: B

Test Bank For ECGs Made Easy 6th Edition Barbara Aehlert

The job of the right side of the heart is to pump unoxygenated blood to and through the lungs to the left side of the heart. This is called the *pulmonary circulation*. The right side of the heart is a low-pressure system.

OBJ: Identify and describe the chambers of the heart and the vessels that enter or leave each.

9. Which side of the heart is a high-pressure system that pumps arterial blood to the systemic circulation?
- Left
 - Right

ANS: A

The left side of the heart is a high-pressure pump. The job of the left heart is to receive oxygenated blood and pump it out to the rest of the body. This is called the *systemic circulation*. The left ventricle is a high-pressure chamber. Its wall is much thicker than the right ventricle (the right ventricle is 3 to 5 mm thick; the left ventricle is 13 to 15 mm thick). This is because the left ventricle must overcome a lot of pressure and resistance from the arteries and contract forcefully in order to pump blood out to the body.

OBJ: Identify and describe the chambers of the heart and the vessels that enter or leave each.

10. The thick, muscular middle layer of the heart wall that contains the atrial and ventricular muscle fibers necessary for contraction is the _____.
- epicardium
 - pericardium
 - myocardium
 - endocardium

ANS: C

The myocardium (middle layer) is a thick, muscular layer that consists of cardiac muscle fibers (cells) responsible for the pumping action of the heart.

OBJ: Describe the structure and function of the coverings of the heart.

11. Blood flows from the right atrium through the _____ valve into the right ventricle.
- mitral
 - aortic
 - pulmonic
 - tricuspid

ANS: D

Blood flows from the right atrium through the tricuspid valve into the right ventricle.

OBJ: Beginning with the right atrium, describe blood flow through the normal heart and lungs to the systemic circulation.

12. Rapid ejection of blood from the ventricular chambers of the heart occurs because the _____ and _____ valves open.
- pulmonic; aortic
 - tricuspid; mitral
 - pulmonic; mitral
 - tricuspid; aortic

Test Bank For ECGs Made Easy 6th Edition Barbara Aehlert

ANS: A

When the ventricles contract, the pulmonic and aortic valves open, allowing blood to flow out of the ventricles.

OBJ: Name and identify the location of the atrioventricular (AV) and semilunar (SL) valves.

13. The base of the heart is found at approximately the level of the _____ rib(s).
- first
 - second
 - fourth
 - fifth and sixth

ANS: B

The base of the heart is its upper portion and is formed mainly by the left atrium, with a small amount of right atrium. It lies at approximately the level of the second rib, immediately in front of the esophagus and descending aorta.

OBJ: Identify the surfaces of the heart.

14. Which of the following are semilunar valves?
- Aortic and pulmonic
 - Aortic and tricuspid
 - Pulmonic and mitral
 - Tricuspid and mitral

ANS: A

The pulmonic and aortic valves are semilunar (SL) valves. The semilunar valves prevent backflow of blood from the aorta and pulmonary arteries into the ventricles.

OBJ: Name and identify the location of the atrioventricular (AV) and semilunar (SL) valves.

15. Blood leaves the left ventricle through the _____ valve to the aorta and its branches and is distributed throughout the body.
- mitral
 - aortic
 - pulmonic
 - tricuspid

ANS: B

When the left ventricle contracts, freshly oxygenated blood flows through the aortic valve into the aorta and out to the body.

OBJ: Beginning with the right atrium, describe blood flow through the normal heart and lungs to the systemic circulation.

16. Blood flows from the left atrium through the _____ valve into the left ventricle.
- mitral
 - aortic
 - pulmonic
 - tricuspid

ANS: A

Blood flows from the left atrium through the mitral (bicuspid) valve into the left ventricle.

Test Bank For ECGs Made Easy 6th Edition Barbara Aehlert

OBJ: Beginning with the right atrium, describe blood flow through the normal heart and lungs to the systemic circulation.

17. The right ventricle expels blood through the _____ valve into the pulmonary trunk.
- mitral
 - aortic
 - pulmonic
 - tricuspid

ANS: C

The right ventricle expels the blood through the pulmonic valve into the pulmonary trunk. The pulmonary trunk divides into a right and left pulmonary artery, each of which carries blood to one lung (pulmonary circuit).

OBJ: Beginning with the right atrium, describe blood flow through the normal heart and lungs to the systemic circulation.

18. The primary neurotransmitters of the sympathetic division of the autonomic nervous system are _____.
- dopamine and acetylcholine
 - muscarine and norepinephrine
 - acetylcholine and epinephrine
 - norepinephrine and epinephrine

ANS: D

When sympathetic nerves are stimulated, the neurotransmitters norepinephrine and epinephrine are released.

OBJ: Compare and contrast the effects of sympathetic and parasympathetic stimulation of the heart.

19. Complete occlusion of the _____ coronary artery, also referred to as the *widow maker*, usually results in sudden death.
- right
 - left main
 - circumflex
 - left anterior descending

ANS: B

Complete occlusion of the left main coronary artery, also referred to as the *widow maker*, usually results in sudden death.

OBJ: Name the primary branches and areas of the heart supplied by the right and left coronary arteries.

20. Stimulation of beta2 receptor sites results in _____.
- increased heart rate
 - peripheral vasoconstriction
 - constriction of renal blood vessels
 - dilation of bronchial smooth muscle

ANS: D

Test Bank For ECGs Made Easy 6th Edition Barbara Aehlert

Beta2 receptor sites are found in the arterioles of the heart, lungs, and skeletal muscle. Stimulation results in dilation. Stimulation of beta2 receptor sites in the smooth muscle of the bronchi results in dilation.

OBJ: Compare and contrast the effects of sympathetic and parasympathetic stimulation of the heart.

21. *Chronotropy* refers to an effect on _____.
a. heart rate
b. force of contraction
c. bronchial smooth muscle
d. speed of conduction through the atrioventricular node

ANS: A

Chrono refers to rate. *Chronotropic effect* refers to a change in heart rate. *Positive chronotropic effect* refers to an increase in heart rate. *Negative chronotropic effect* refers to a decrease in heart rate.

OBJ: Compare and contrast the effects of sympathetic and parasympathetic stimulation of the heart.

22. The left main coronary artery divides into the _____ branches.
a. marginal and circumflex
b. marginal and anterior descending
c. anterior and posterior descending
d. anterior interventricular artery descending and circumflex

ANS: D

The left main coronary artery supplies oxygenated blood to its two primary branches: the left anterior descending (LAD) (also called the *anterior interventricular*) artery and the circumflex artery (CX).

OBJ: Name the primary branches and areas of the heart supplied by the right and left coronary arteries.

23. The primary neurotransmitter of the parasympathetic division of the autonomic nervous system is _____.
a. dopamine
b. muscarine
c. acetylcholine
d. norepinephrine

ANS: C

Acetylcholine (Ach) is a chemical messenger (neurotransmitter) released when parasympathetic nerves are stimulated. Ach binds to parasympathetic receptors.

OBJ: Compare and contrast the effects of sympathetic and parasympathetic stimulation of the heart.

24. The _____ artery supplies the right atrium and ventricle with blood.
a. right coronary
b. left main coronary
c. left circumflex
d. left anterior descending

ANS: A

Test Bank For ECGs Made Easy 6th Edition Barbara Aehlert

The right coronary artery supplies the right atrium and ventricle with blood.

OBJ: Name the primary branches and areas of the heart supplied by the right and left coronary arteries.

25. The tricuspid valve is _____.
- a semilunar valve
 - located between the left ventricle and aorta
 - located between the right atrium and right ventricle
 - located between the right ventricle and pulmonary artery

ANS: C

The tricuspid valve is located between the right atrium and right ventricle.

OBJ: Identify and describe the location of the atrioventricular (AV) and semilunar (SL) valves.

26. When the left ventricle contracts, freshly oxygenated blood flows through the _____ valve into the _____.
- aortic; aorta
 - mitral; right atrium
 - tricuspid; right ventricle
 - pulmonic; pulmonary arteries

ANS: A

When the ventricles contract, the semilunar valves open, allowing blood to flow out of the ventricles. When the right ventricle contracts, blood that is low in oxygen flows through the pulmonic valve into the right and left pulmonary arteries. When the left ventricle contracts, freshly oxygenated blood flows through the aortic valve into the aorta and out to the body.

OBJ: Identify and describe the location of the atrioventricular (AV) and semilunar (SL) valves.

27. Thin strands of fibrous connective tissue extend from the atrioventricular (AV) valves to the papillary muscles and prevent the AV valves from bulging back into the atria during ventricular systole. These strands are called _____.
- cardiac cilia
 - Purkinje fibers
 - papillary muscles
 - chordae tendineae

ANS: D

Chordae tendineae are thin strands of connective tissue. On one end, they are attached to the underside of the AV valves. On the other end, they are attached to small mounds of myocardium called papillary muscles. Papillary muscles project inward from the lower portion of the ventricular walls. When the ventricles contract and relax, so do the papillary muscles. The papillary muscles adjust their tension on the chordae tendineae, preventing them from bulging too far into the atria. Cardiac cilia are not present. Purkinje fibers are related to the electrical system of the heart and not fibrous connective tissue.

OBJ: Identify and describe the location of the atrioventricular (AV) and semilunar (SL) valves.

COMPLETION

Test Bank For ECGs Made Easy 6th Edition Barbara Aehlert

1. _____ is the period during which a heart chamber is contracting and blood is being ejected.

ANS: Systole

OBJ: Identify and discuss each phase of the cardiac cycle.

2. The thick, muscular middle layer of the heart wall that contains the atrial and ventricular muscle fibers necessary for contraction is the _____.

ANS: myocardium

OBJ: Identify the three cardiac muscle layers.

3. The _____ chambers receive blood from the vena cava and coronary sinus.

ANS: right atrium

OBJ: Identify and describe the chambers of the heart and the vessels that enter or leave each.

4. The inferior outer surface of the heart is also called the _____ surface.

ANS: diaphragmatic

OBJ: Describe the location of the heart.

5. The _____ are the heart chambers that pump blood.

ANS: ventricles

OBJ: Identify and describe the chambers of the heart and the vessels that enter or leave each.

6. _____ is the period of relaxation during which a heart chamber is filling.

ANS: Diastole

OBJ: Identify and discuss each phase of the cardiac cycle.

TRUE/FALSE

1. Stimulation of beta-adrenergic receptor sites will result in peripheral vasoconstriction.

ANS: F

Beta receptor sites are divided into beta1 and beta2. Beta1 receptors are found in the heart and kidneys. Stimulation of beta1 receptor sites in the heart results in increased heart rate, contractility, and ultimately irritability of cardiac cells. Stimulation of beta1 receptor sites in the kidneys results in the release of renin into the blood. Renin promotes the production of angiotensin, a powerful vasoconstrictor. Beta2 receptor sites are found in the arterioles of the heart, lungs, and skeletal muscle. Stimulation results in dilation. Stimulation of beta2 receptor sites in the smooth muscle of the bronchi results in dilation.

OBJ: Compare and contrast the effects of sympathetic and parasympathetic stimulation of the heart.