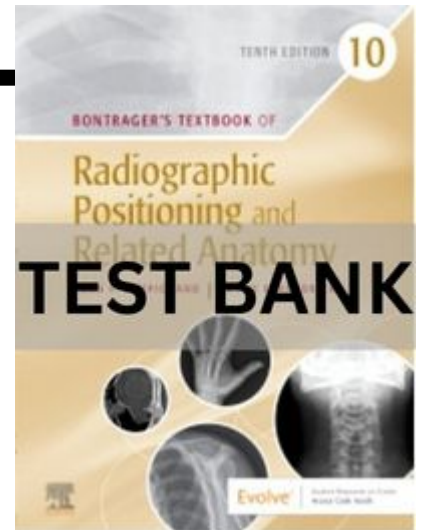


**Chapter 01: Terminology, Positioning, and Imaging Principles**  
**Lampignano: Bontrager's Textbook of Radiographic**  
**Positioning and Related Anatomy, 10th Edition**

---



**MULTIPLE CHOICE**

1. What type of tissue binds together and supports the various structures of the body?
  - a. Epithelial
  - b. Connective
  - c. Muscular
  - d. Nervous

ANS: B

2. The lowest level of structural organization in the human body is the \_\_\_\_\_ level.
  - a. molecular
  - b. cellular
  - c. chemical
  - d. atomic

ANS: C

3. What type of tissue covers internal and external surfaces of the body?
  - a. Muscular
  - b. Connective
  - c. Nervous
  - d. Epithelial

ANS: D

4. How many individual body systems comprise the human body?
  - a. 22
  - b. 13
  - c. 10
  - d. 8

ANS: C

5. How many separate bones are found in the adult human body?
  - a. 181
  - b. 215
  - c. 206
  - d. 236

ANS: C

6. Which system of the human body is responsible for the elimination of solid waste?
- Circulatory
  - Respiratory
  - Urinary
  - Digestive

ANS: D

7. Which of the following systems of the human body includes all ductless glands of the body?
- Endocrine
  - Integumentary
  - Muscular
  - Glandular

ANS: A

8. Which of the following body systems helps to regulate body temperature?
- Circulatory
  - Urinary
  - Endocrine
  - Nervous

ANS: A

9. Which of the following bones is part of the axial skeleton?
- Radius
  - Hip bone
  - Clavicle
  - Sternum

ANS: D

10. How many bones are there in the adult axial skeleton?
- 206
  - 80
  - 54
  - 126

ANS: B

11. What is the name of the small oval-shaped bone found in tendons?
- Wormian
  - Tendinous
  - Irregular
  - Sesamoid

ANS: D

12. Which of the following bones is classified as a long bone?
- Carpal bone
  - Scapula
  - Cranium

d. Humerus

ANS: D

13. What is the name of the dense fibrous membrane that covers bone?

- a. Cancellous portion
- b. Periosteum
- c. Diploë
- d. Medullary portion

ANS: B

14. Which of the following bones is classified as a short bone?

- a. Vertebrae
- b. Phalanges (toes)
- c. Scapulae
- d. Carpal (wrist bones)

ANS: D

15. Which of the following is a secondary growth center for endochondral ossification?

- a. Diaphysis
- b. Epiphyses
- c. Metaphysis
- d. Articular cartilage

ANS: B

16. Which aspect of the long bones is responsible for the production of red blood cells?

- a. Compact bone
- b. Periosteum
- c. Medullary cavity
- d. Spongy or cancellous bone

ANS: D

17. Examples of “flat” bones are the:

- a. calvaria, ribs, scapulae, and sternum.
- b. ribs, sternum, patella, and ilia of pelvis.
- c. sternum, scapulae, ilia of pelvis, and base of cranium.
- d. sternum and ilia of pelvis only.

ANS: A

18. What is the primary center for bone growth termed?

- a. Epiphyses
- b. Diaphysis
- c. Metaphysis
- d. Epiphyseal plate

ANS: B

19. Which of the following is NOT a functional classification of joints?

- a. Synarthrosis

- b. Amphiarthrosis
- c. Cartilaginous
- d. Diarthrosis

ANS: C

20. The structural term for a freely movable joint is:
- a. fibrous.
  - b. cartilaginous.
  - c. synovial.
  - d. gomphosis.

ANS: C

21. Which of the following joints displays flexion and extension type of movement primarily?
- a. Pivot
  - b. Ellipsoidal
  - c. Saddle
  - d. Ginglymus

ANS: D

22. Which of the following joints is NOT a synovial joint?
- a. Skull sutures
  - b. Elbow joint
  - c. Hip joint
  - d. Proximal radioulnar joint

ANS: A

23. Which of the following is classified as a saddle (sellar) joint?
- a. Ankle joint
  - b. Temporomandibular joint
  - c. Knee joint
  - d. Intercarpal joint

ANS: A

24. Which of the following is classified as a bicondylar joint?
- a. Shoulder joint
  - b. Temporomandibular joint
  - c. First and second cervical vertebra joint
  - d. Distal radioulnar joint

ANS: B

25. An upright position with the arms abducted, palms forward, and head forward describes the \_\_\_\_\_ position.
- a. anteroposterior (AP)
  - b. decubitus
  - c. anatomic
  - d. oblique

ANS: C

26. A representation of the patient's anatomic structures that can be obtained, viewed, manipulated, and stored digitally is the definition for:
- radiographic film.
  - radiography.
  - radiographic image.
  - radiographic examination.

ANS: C

27. The vertical plane that divides the body into equal right and left halves describes the \_\_\_\_\_ plane.
- coronal
  - median or midsagittal
  - longitudinal
  - horizontal

ANS: B

28. A longitudinal plane that divides the body into equal anterior and posterior parts is the \_\_\_\_\_ plane.
- midcoronal
  - midsagittal
  - horizontal
  - oblique

ANS: A

29. Which of the following terms describes the sole of the foot?
- Palmar
  - Dorsum
  - Volar
  - Plantar

ANS: D

30. Which term describes the back or posterior aspect of the hand?
- Dorsum pedis
  - Dorsum manus
  - Palmar
  - Volar

ANS: B

31. The position in which the head is lower than the feet:
- Trendelenburg.
  - lithotomy.
  - Fowler.
  - recumbent.

ANS: A

32. Which term describes lying down in any position?
- Horizontal

- b. Fowler
- c. Recumbent
- d. Anatomic

ANS: C

33. A recumbent position in which the patient is lying on the right anterior surface with the body rotated toward the image receptor is termed:
- a. right posterior oblique.
  - b. left anterior oblique.
  - c. Sims' position.
  - d. Fowler position.

ANS: A

34. A patient is lying on her back facing the x-ray tube. The right side of her body is turned 20 degrees toward the image receptor. What is this radiographic position?
- a. LPO (left posterior oblique)
  - b. RPO (right posterior oblique)
  - c. RAO (right anterior oblique)
  - d. LAO (left anterior oblique)

ANS: B

35. A patient is erect with the left side directly against the image receptor. The central ray (CR) enters the right side of the body. What is this radiographic position?
- a. Right lateral
  - b. Left lateral decubitus
  - c. Left lateral
  - d. Dorsal decubitus

ANS: C

36. A patient is lying on her back. The x-ray tube is horizontally directed with the CR entering the right side of the body. The image receptor is adjacent to the left side of the body. What is the radiographic position?
- a. Left lateral decubitus
  - b. Left lateral
  - c. Right lateral decubitus
  - d. Dorsal decubitus

ANS: D

37. A patient is erect facing the image receptor. The left side of the body is turned 45 degrees toward the image receptor. The CR enters the posterior aspect of the body and exits the anterior. What is this radiographic position?
- a. LAO
  - b. LPO
  - c. Left lateral
  - d. Posteroanterior (PA)

ANS: A

38. What type of projection is created with the CR directed along or parallel to the long axis of a structure or anatomic part?
- Axial
  - Tangential
  - Lordotic
  - Transthoracic

ANS: A

39. A projection in which the CR skims a body part to project it in profile is termed:
- tangential.
  - lordotic.
  - axial.
  - decubitus.

ANS: A

40. What is the general term for a position in which the long axis of the body is angled in relationship to the image receptor rather than the central ray (e.g., special chest projection)?
- Axial
  - Trendelenburg
  - Decubitus
  - Lordotic

ANS: D

41. The opposite term for supination is:
- protraction.
  - adduction.
  - pronation.
  - retraction.

ANS: C

42. Which of the following positions is often used to insert a rectal enema tip before a barium enema study?
- Fowler
  - Modified Sims'
  - Lithotomy
  - Trendelenburg

ANS: B

43. A dorsoplantar projection would be a radiographic study of:
- any anatomic region.
  - the hand.
  - the foot.
  - the skull.

ANS: C

44. Moving the foot and toes downward is:
- eversion.
  - inversion.

- c. dorsiflexion.
- d. plantar flexion.

ANS: D

45. Movement in the form of a circle is the definition for:
- a. rotation.
  - b. retraction.
  - c. circumduction.
  - d. protraction.

ANS: C

46. Which of the following terms is the opposite of ipsilateral?
- a. Medial
  - b. Deviation
  - c. Contralateral
  - d. Axialateral

ANS: C

47. The radiographic term *projection* is defined as:
- a. general position of the patient.
  - b. path or direction of the central ray.
  - c. radiographic image as seen from the vantage of the image receptor.
  - d. computer-assisted image.

ANS: B

48. Which of following is NOT one of the evaluation criteria applied in the evaluation of images?
- a. Patient condition
  - b. Anatomy demonstrated
  - c. Collimation and CR
  - d. Exposure criteria

ANS: A

49. A patient enters the emergency department (ED) with a piece of wire in the palm of the hand. What is the minimum number of projections required to be taken for this radiographic study?
- a. One
  - b. Two
  - c. Three
  - d. Four or more

ANS: B

50. Which of the following radiographic procedures often only requires a single AP projection be taken?
- a. Finger
  - b. Ribs
  - c. Chest
  - d. Pelvis

ANS: D



51. What is the final step taken before making the exposure during a positioning routine?
- a. Image receptor centering
  - b. Placing anatomic markers on image receptor
  - c. Ensuring correct gonadal shield placement
  - d. Collimation adjustments

ANS: C

52. What is the minimal number of projections taken for a study of the femur?
- a. One
  - b. Two
  - c. Three
  - d. Four

ANS: B

53. What is the minimal number of projections taken for a study of the right hip?
- a. One
  - b. Two
  - c. Three
  - d. Four

ANS: B

54. What is the minimal number of projections taken for a postreduction (to realign a fracture) study of the ankle?
- a. One
  - b. Two
  - c. Three
  - d. Four

ANS: B

55. What is the minimal number of projections taken for a study of the elbow?
- a. One
  - b. Two
  - c. Three
  - d. Four

ANS: C

56. A patient is erect with the left side of his chest placed against the image receptor. The central ray enters the right side of the upper chest and exits the left. Which specific position has been performed?
- a. Dorsal decubitus
  - b. Transthoracic lateral
  - c. Right lateral
  - d. Ventral decubitus

ANS: B

57. A patient is erect facing the x-ray tube and leaning the shoulders backward 20 to 30 degrees toward the IR. The central ray is perpendicular to the IR. What specific position has been performed?
- a. Lordotic
  - b. Oblique
  - c. Kyphotic
  - d. Tangential

ANS: A

58. The top of the foot is placed against the image receptor with the perpendicular central ray entering the sole of the foot. What specific projection has been performed?
- a. Transpedal
  - b. Plantodorsal
  - c. Axial dorsoplantar
  - d. Tangential plantodorsal

ANS: B

59. The patient is lying on her right side on a cart. The anterior surface of the patient is against the image receptor. A horizontal central ray enters the posterior surface and exits the anterior surface of the body. What specific projection/position has been performed?
- a. AP
  - b. PA
  - c. Right lateral decubitus
  - d. Left lateral decubitus

ANS: C

60. The patient's head and neck are hyperextended with the top of the skull directly against the image receptor. The central ray enters just below the chin. Which specific projection has been performed?
- a. Submentovertical
  - b. Acanthioparietal
  - c. Parietoacanthial
  - d. Verticosubmental

ANS: A

61. Which of the following is NOT one of the four image quality factors of an analog radiograph?
- a. Contrast
  - b. Spatial resolution
  - c. Source-image receptor distance (SID)
  - d. Distortion

ANS: C

62. The amount of blackness seen on a radiograph is called:
- a. fog.
  - b. scatter.
  - c. contrast.
  - d. density.

ANS: D