


Anatomy of Orofacial Structures 8th Edition Test Bank

Chapter 01: Oral Cavity

Brand/Isselhard: Anatomy of Orofacial Structures, 8th Edition



MULTIPLE CHOICE

1. A diastema is a space between two teeth in the same arch. When this occurs between the maxillary central incisors, it is often the result of a pronounced labial frenum.
 - a. Both statements are true.
 - b. The first statement is true; the second statement is false.
 - c. The first statement is false; the second statement is true.
 - d. Both statements are false.

ANS: A

A space, or lack of contact area, between any two teeth in the same arch is called a diastema. When a diastema occurs between the maxillary central incisors, it is often the result of a pronounced labial frenum extending to the crest of the alveolar ridge and possibly over the ridge. This band of firm connective tissue causes the erupting incisors to be pushed aside resulting in a diastema, or space. Correction of a diastema usually involves surgical removal, or cutting, of the frenal tissue between teeth.

REF: p. 3

OBJ: To describe the boundaries and sub-boundaries of the oral cavity and the structures in each area

NAT: CDA: GC I.A.6. Identify basic oral anatomy and physiology, including but not limited to: oral cavity. STA: NBDHE: SB 1.1.2.1. General dental anatomy

TOP: BLOOM: Remembering

2. Torus palatinus is seen on the
 - a. soft palate
 - b. hard palate
 - c. alveolar ridge
 - d. oral pharynx

ANS: B

Torus palatinus is excess bone growth and occurs in the midline of the hard palate. It may grow to varying sizes and is generally only a problem when the construction of a maxillary denture is necessary. In health, such bony protuberances, or excess bone growths, do not occur on the soft palate, alveolar ridge, or oral pharynx.

REF: p. 5

OBJ: To define the terms vestibule, oral cavity proper, mucobuccal fold, frenum, alveolar mucosa, gingiva, exostoses, torus palatinus, and torus mandibularis

NAT: CDA: GC I.A.2. Identify basic oral anatomy and physiology, including but not limited to:

Anatomy of Orofacial Structures 8th Edition Test Bank

bones. STA: NBDHE: SB 1.1.2.1. General dental anatomy
TOP: BLOOM: Remembering

3. Contraction of which muscle raises the tongue upward?
- Mylohyoid
 - Palatopharyngeal
 - Palatoglossal
 - Levator glossal

ANS: A

Contraction of the mylohyoid muscle raises the tongue. The palatopharyngeal muscle and the palatoglossal muscle form the posterolateral borders of the oral cavity. There is not a muscle by the name of levator glossal.

REF: p. 7

OBJ: To define the landmarks in the floor of the mouth and the hard and soft palate and the structures that form them

NAT: CDA: GC I.A.4. Identify basic oral anatomy and physiology, including but not limited to: muscles. STA: NBDHE: SB 1.1.2.1. General dental anatomy

TOP: BLOOM: Remembering

4. The oral vestibule is partially bordered by the lips and cheeks. The oral cavity proper extends posteriorly to the soft palate.
- Both statements are true.
 - The first statement is true; the second statement is false.
 - The first statement is false; the second statement is true.
 - Both statements are false.

ANS: B

The oral vestibule is the space or potential space that exists between the lips or cheeks and teeth. In an edentulous person, the vestibule would extend between the lips or cheeks and the alveolar ridges. The oral cavity proper is surrounded by teeth or alveolar ridges and extends all the way back to the palatine tonsils. This includes the region from the floor of the mouth upward to the hard and soft palates.

REF: p. 2

OBJ: To describe the boundaries and sub-boundaries of the oral cavity and the structures in each area

NAT: CDA: GC I.A.6. Identify basic oral anatomy and physiology, including but not limited to: oral cavity. STA: NBDHE: SB 1.1.2.1. General dental anatomy

TOP: BLOOM: Remembering

5. Each of the following is true of the uvula EXCEPT one. Which one is the EXCEPTION?
- It is located at the most posterior portion of the hard palate.
 - It is located at the midline.
 - It is a downwardly projecting muscle.
 - It is necessary for swallowing.

ANS: D

The uvula is a downwardly projecting muscular tissue located at the midline of the most posterior portion of the hard palate. It is NOT necessary for swallowing.

REF: p. 6

OBJ: To define the landmarks in the floor of the mouth and the hard and soft palate and the structures

Anatomy of Orofacial Structures 8th Edition Test Bank

that form them

NAT: CDA: GC I.A.6. Identify basic oral anatomy and physiology, including but not limited to: oral cavity. STA:

NBDHE: SB 1.1.2.1. General dental anatomy

TOP: BLOOM: Remembering

6. The circumvallate papillae are located on the hard palate, buccal mucosa, and floor of the mouth. The papillae found on the tongue are the filiform, fungiform, vallate, foliate, and incisive.
- Both statements are true.
 - The first statement is true; the second statement is false.
 - The first statement is false; the second statement is true.
 - Both statements are false.

ANS: D

All papillae listed in both statements are located on the tongue with the exception of the incisive papilla, which is located on the hard palate. Note that the incisive papilla is a singular structure, thus the different spelling. There are no papillae located on either the buccal mucosa or the floor of the mouth.

REF: p. 7

OBJ: To define the landmarks in the floor of the mouth and the hard and soft palate and the structures that form them

NAT: CDA: GC I.A.6. Identify basic oral anatomy and physiology, including but not limited to: oral cavity. STA:

NBDHE: SB 1.1.2.1. General dental anatomy

TOP: BLOOM: Remembering

7. Each of the following structures can readily be viewed when examining the oral cavity EXCEPT one. Which one is the EXCEPTION?
- Fovea palatinae
 - Tonsillar pillars
 - Laryngeal pharynx
 - Sublingual fold

ANS: C

The laryngeal pharynx is located below the oral pharynx and cannot be seen while examining the oral cavity. The fovea palatinae, the tonsillar pillars, and the sublingual fold can be seen when examining the oral cavity. Fovea palatinae are small depressions in mucosa on either side of the posterior nasal spine indicating the junction of the hard and soft palate. Tonsillar pillars are folds of tissue that partially surround the tonsils. The sublingual fold extends backward on either side of the floor of the mouth and is situated just superior to the submandibular gland.

REF: p. 2 | pp. 6-7

OBJ: To describe the boundaries and sub-boundaries of the oral cavity and the structures in each area

NAT: CDA: GC I.A.6. Identify basic oral anatomy and physiology, including but not limited to: oral cavity. STA:

NBDHE: SB 1.1.2.1. General dental anatomy

TOP: BLOOM: Remembering

8. Each of the following structures is located within the hard palate EXCEPT one. Which one is the EXCEPTION?
- Incisive papilla
 - Rugae

Anatomy of Orofacial Structures 8th Edition Test Bank

- c. Greater palatine foramina
- d. The anterior and posterior pillars

ANS: D

The anterior and posterior pillars are located posterior to the soft palate. The posterior pillar is also called the palatopharyngeal arch or fold. The anterior pillar is also called the palatoglossal arch or fold. The tonsils lie between the anterior and posterior pillars. The incisive papilla and rugae are located on the anterior portion of the hard palate. The greater palatine foramina are located in the posterior portions of the hard palate lingual to the second and third maxillary molars.

REF: pp. 5-6

OBJ: To define the landmarks in the floor of the mouth and the hard and soft palate and the structures that form them

NAT: CDA: GC I.A.6. Identify basic oral anatomy and physiology, including but not limited to: oral cavity. STA:

NBDHE: SB 1.1.2.1. General dental anatomy

TOP: BLOOM: Remembering

9. The small bony growths that commonly occur on the buccal cortical plate of the maxillae and the mandible are called
- a. torus palatinus
 - b. mandibular tori
 - c. exostoses
 - d. maxillary tuberosity

ANS: C

Exostoses, small bony growths that occur on the buccal cortical plate on the mandible and the maxillae, are seen in a large portion of the population. They are normally inconsequential unless they become tender or a denture is needed. Exostoses occur more frequently on the mandible than on the maxillae.

Torus palatinus are excess bony growths that commonly occur in the midline of the palate.

Mandibular tori are bony swellings that frequently occur on the lingual surface of the mandible at the canine area. The maxillary tuberosity is a rounded bony protrusion in the area of the third molar.

REF: p. 4

OBJ: To define the terms vestibule, oral cavity proper, mucobuccal fold, frenum, alveolar mucosa, gingiva, exostoses, torus palatinus, and torus mandibularis

NAT: CDA: GC I.A.2. Identify basic oral anatomy and physiology, including but not limited to: bones. STA:

NBDHE: SB 1.1.2.1. General dental anatomy

TOP: BLOOM: Remembering

10. Which structure is the MOST vascular in appearance?
- a. Mucogingival junction
 - b. Alveolar mucosa
 - c. Labial frenum
 - d. Gingiva

ANS: B

Anatomy of Orofacial Structures 8th Edition Test Bank

The alveolar mucosa, a thin layer of loosely attached and movable tissue, covers a highly vascular area. The presence of blood vessels immediately under this relatively thin mucosa is responsible for the general reddish color. By contrast, the mucogingival junction that divides the attached gingiva from the alveolar mucosa appears more pink in color. The gingiva and labial frenum also appear pink in color.

REF: p. 2

OBJ: To define the terms vestibule, oral cavity proper, mucobuccal fold, frenum, alveolar mucosa, gingiva, exostoses, torus palatinus, and torus mandibularis

NAT: CDA: GC I.A.6. Identify basic oral anatomy and physiology, including but not limited to: oral cavity. STA: NBDHE: SB 1.1.2.1. General dental anatomy

TOP: BLOOM: Remembering

11. Although a patient presenting with painful areas throughout the oral cavity or a child presenting with gingival bleeding in the presence of excellent oral hygiene should be monitored carefully, referral to a dental specialist or physician is not indicated. A patient with a red and painful tongue does warrant such a referral as does a patient with moderate plaque on all teeth.
- Both statements are true.
 - The first statement is true; the second statement is false.
 - The first statement is false, the second statement is true.
 - Both statements are false.

ANS: D

Of the four situations presented in this two-part question, only the patient with moderate plaque on all teeth does NOT warrant referral to a specialist. This patient should receive appropriate oral hygiene instructions, oral debridement, and be carefully monitored with short re-care appointments. The remaining three oral conditions described in the question describe conditions suggestive of systemic involvement and warrant further investigation, typically referral to a dental specialist or physician. In particular, gingival bleeding in the presence of excellent oral hygiene is a possible early sign of leukemia.

REF: p. 8

OBJ: To differentiate normal from abnormal anatomy in the oral cavity and to ensure a follow-up examination

NAT: CDA: GC I.A.1. Identify basic oral and dental anatomy, physiology and development, including but not limited to: oral cavity. STA: NBDHE: SB 1.1.2.1. General dental anatomy

TOP: BLOOM: Analyzing

12. Which structure is most closely located to the lingual frenum?
- Sublingual caruncle
 - Sublingual salivary gland
 - Sublingual fold
 - Lingual tonsils
 - All of the above

ANS: A

The sublingual caruncle, a small elevation on each side of the base of the lingual frenum, is the opening for the submandibular and sublingual salivary glands. Of the structures provided in the question, it is located most closely to the lingual frenum. The sublingual fold extends posteriorly from the sublingual caruncle. The lingual tonsils are located at the base of the tongue.

Anatomy of Orofacial Structures 8th Edition Test Bank

REF: p. 7

OBJ: To define the landmarks in the floor of the mouth and the hard and soft palate and the structures that form them

NAT: CDA: GC I.A.6. Identify basic oral anatomy and physiology, including but not limited to: oral cavity. STA: NBDHE: SB 1.1.2.1. General dental anatomy

TOP: BLOOM: Remembering

13. The term for misplaced sebaceous glands occurring in the oral cavity is rugae. These harmless, yellowish granular structures occur in about 60% to 80% of the population.
- Both statements are true.
 - The first statement is true; the second statement is false.
 - The first statement is false; the second statement is true.
 - Both statements are false.

ANS: C

Fordyce granules are misplaced sebaceous glands found in the oral cavity. These glands are normally associated with hair follicles, which are normally located in the skin. The most common locations for Fordyce granules are the lips, cheeks, and retromolar pads. Rugae are hard transverse ridges of epithelial and connective tissue located in the anterior portion of the hard palate.

REF: p. 5

OBJ: To differentiate normal from abnormal anatomy in the oral cavity and to ensure a follow-up examination

NAT: CDA: GC I.A.6. Identify basic oral anatomy and physiology, including but not limited to: oral cavity. STA: NBDHE: SB 1.1.2.1. General dental anatomy

TOP: BLOOM: Remembering

14. Of the following structures, which is the MOST susceptible to trauma?
- Hard palate
 - Buccal mucosa
 - Floor of the mouth
 - Dorsal surface of the tongue
 - Attached gingiva

ANS: C

Although any oral tissue may be traumatized, the tissue in the floor of the mouth is one of the thinnest and thus very conducive to trauma. The hard palate and the attached gingiva have a more protective, fibrous nature. The dorsal (top) tongue and the buccal mucosa also have more protective features than does the mucosal lining on the floor of the mouth. Not listed as a selection, the ventral (lower) surface of the tongue is quite vulnerable to trauma.

REF: p. 7

OBJ: To define the landmarks in the floor of the mouth and the hard and soft palate and the structures that form them

NAT: CDA: GC I.A.6. Identify basic oral anatomy and physiology, including but not limited to: oral cavity. STA: NBDHE: SB 1.1.2.1. General dental anatomy

TOP: BLOOM: Remembering

15. A generally healthy man in his forties is curious about “little raised yellow spots” on his buccal mucosa. He has noticed them in the past but they do not seem to cause problems or become larger, so has not previously asked about them. These areas are MOST likely
- vallate papillae

Anatomy of Orofacial Structures 8th Edition Test Bank

- b. Kaposi's spots
- c. Fordyce granules
- d. measles

ANS: C

Fordyce granules are ectopic, or misplaced, sebaceous glands that occur on oral mucosal surfaces. They appear as small raised yellowish or whitish spots. Although alarming to patients, these formations are harmless. Vallate papillae, also called circumvallate papillae, are the large V-shaped row of taste buds located on the posterior dorsum of the tongue. Kaposi's spots, associated with immunodeficiency, are red and painful. Measles can appear anywhere on the body, including the oral cavity, and are red in color.

REF: p. 4

OBJ: To differentiate normal from abnormal anatomy in the oral cavity and to ensure a follow-up examination

NAT: CDA: GC I.A.3. Identify basic oral anatomy and physiology, including but not limited to: glands/lymphatics. STA: NBDHE: SB 1.1.2.1. General dental anatomy

TOP: BLOOM: Understanding

16. Fordyce granules normally function as
- a. taste buds
 - b. a characteristic of a malignancy
 - c. sebaceous glands
 - d. an infectious viral illness

ANS: C

Fordyce granules are misplaced sebaceous glands that appear as very small yellowish granular structures on oral mucosal surfaces in the oral cavity of 60% to 80% of the population. Sebaceous glands normally occur in the skin; when they are present in the oral cavity they are considered misplaced, or ectopic. Although Fordyce granules may be alarming to patients, they are harmless. They most commonly occur in the mucosa of the lips, cheeks, retromolar pads, and gingival tissues.

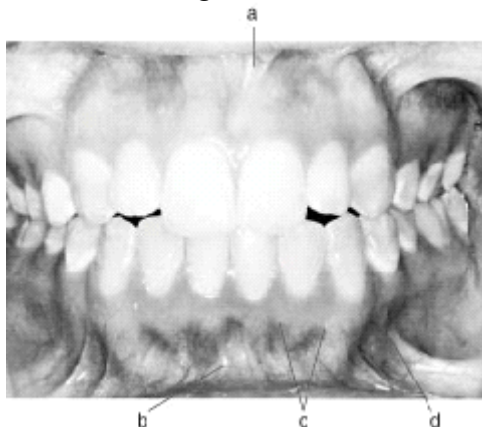
REF: p. 4

OBJ: To differentiate normal from abnormal anatomy in the oral cavity and to ensure a follow-up examination

NAT: CDA: GC I.A.3. Identify basic oral anatomy and physiology, including but not limited to: glands/lymphatics. STA: NBDHE: SB 1.1.2.1. General dental anatomy

TOP: BLOOM: Remembering

17. In the following illustration, structure "a" is the



Anatomy of Orofacial Structures 8th Edition Test Bank

- a. mucobuccal fold
- b. maxillary labial frenum
- c. mandibular labial frenum
- d. mucogingival junction

ANS: B

At the midline of the upper lip, a fold of connective tissue known as the maxillary labial frenum can be found. A corresponding structure, the mandibular labial frenum, is present at the midline of the lower lip. The upper frenum is usually more pronounced than the lower. Both structures, as well as additional less well-defined frena, serve to attach the lips to the arch and contain only connective tissue. Structure “b” is the mandibular labial frenum. Structure “c” is the mucogingival junction. Structure “d” is the mucobuccal fold.

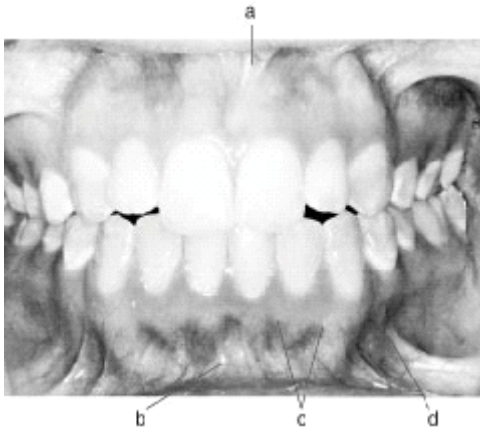
REF: pp. 3-4

OBJ: To define the terms vestibule, oral cavity proper, mucobuccal fold, frenum, alveolar mucosa, gingiva, exostoses, torus palatinus, and torus mandibularis

NAT: CDA: GC I.A.6. Identify basic oral anatomy and physiology, including but not limited to: oral cavity. STA: NBDHE: SB 1.1.2.1. General dental anatomy

TOP: BLOOM: Remembering

18. In the following illustration, structure “b” is the



- a. mucobuccal fold
- b. mucogingival junction
- c. maxillary labial frenum
- d. mandibular labial frenum

ANS: D

At the midline of the lower lip, a fold of connective tissue known as the mandibular labial frenum can be found. A mandibular frenal attachment that extends too close to the gingiva may contribute to gingival recession. A corresponding structure, the maxillary labial frenum, is present at the midline of the upper lip. Both structures, as well as additional less well-defined frena, serve to attach the lips to the arch and contain only connective tissue. Structure “a” is the maxillary labial frenum. Structure “c” is the mucogingival junction. Structure “d” is the mucobuccal fold.

REF: pp. 3-4

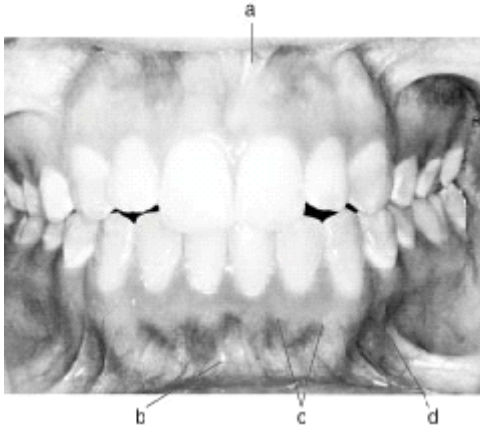
OBJ: To define the terms vestibule, oral cavity proper, mucobuccal fold, frenum, alveolar mucosa, gingiva, exostoses, torus palatinus, and torus mandibularis

NAT: CDA: GC I.A.6. Identify basic oral anatomy and physiology, including but not limited to: oral cavity. STA: NBDHE: SB 1.1.2.1. General dental anatomy

TOP: BLOOM: Remembering

Anatomy of Orofacial Structures 8th Edition Test Bank

19. In the following illustration, structure “c” is the



- a. mucogingival junction
- b. mandibular labial frenum
- c. maxillary labial frenum
- d. mucobuccal fold

ANS: A

The mucogingival junction is the demarcation between the attached gingiva and the more loosely connected alveolar mucosa. A change in tissue color is evident at the mucogingival junction. The attached gingiva is pink in color whereas the alveolar mucosa is considerably more red. Structure “a” is the maxillary labial frenum. Structure “b” is the mandibular labial frenum. Structure “d” is the mucobuccal fold.

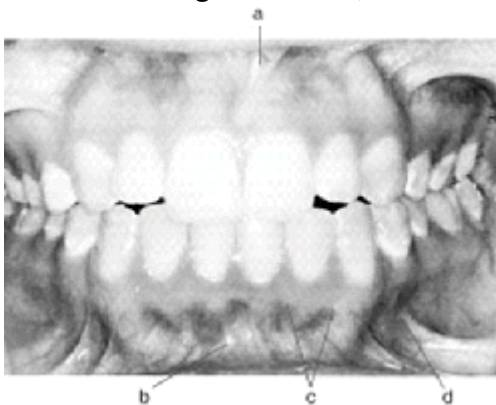
REF: pp. 3-4

OBJ: To describe the boundaries and sub-boundaries of the oral cavity and the structures in each area

NAT: CDA: GC I.A.6. Identify basic oral anatomy and physiology, including but not limited to: oral cavity. STA: NBDHE: SB 1.1.2.1. General dental anatomy

TOP: BLOOM: Remembering

20. In the following illustration, structure “d” is the



- a. mandibular labial frenum
- b. mucogingival junction
- c. mucobuccal fold
- d. maxillary labial frenum

ANS: C

Anatomy of Orofacial Structures 8th Edition Test Bank

The point at which the mucosa of the lips or cheeks joins the gingival tissue is known as the mucobuccal fold or mucolabial fold. These structures are generally located slightly distal to the canine teeth and are quite evident. Structure “a” is the maxillary labial frenum. Structure “b” is the mandibular labial frenum. Structure “c” is the mucogingival junction.

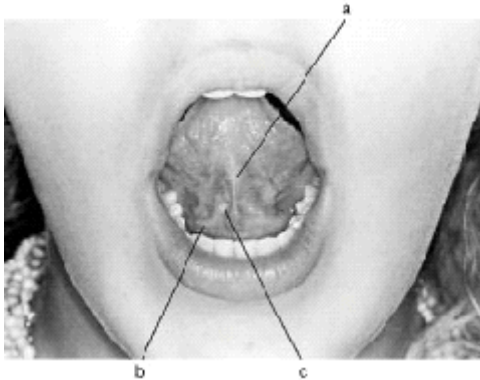
REF: pp. 3-4

OBJ: To define the terms vestibule, oral cavity proper, mucobuccal fold, frenum, alveolar mucosa, gingiva, exostoses, torus palatinus, and torus mandibularis

NAT: CDA: GC I.A.6. Identify basic oral anatomy and physiology, including but not limited to: oral cavity. STA: NBDHE: SB 1.1.2.1. General dental anatomy

TOP: BLOOM: Remembering

21. In the following illustration, structure “a” is the



- a. sublingual fold
- b. lingual frenum
- c. sublingual caruncle

ANS: B

The lingual frenum, also called the lingual frenulum, extends from an area near the tip of the ventral surface of the tongue to the floor of the mouth. If this frenum is attached close to the tip of the tongue and is rather short, the tongue movement will be limited resulting in a condition called ankyloglossia, or tongue tie. In the illustration, structure “b” is the sublingual fold; structure “c” is the sublingual caruncle.

REF: p. 7

OBJ: To define the terms vestibule, oral cavity proper, mucobuccal fold, frenum, alveolar mucosa, gingiva, exostoses, torus palatinus, and torus mandibularis

NAT: CDA: GC I.A.6. Identify basic oral anatomy and physiology, including but not limited to: oral cavity. STA: NBDHE: SB 1.1.2.1. General dental anatomy

TOP: BLOOM: Remembering

22. In the following illustration, structure “b” is the