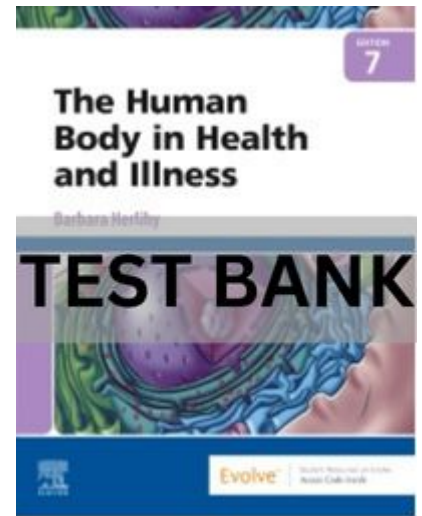


The Human Body in Health and Illness 7th Edition Test Bank

Chapter 01: Introduction to the Human Body

Herlihy: The Human Body in Health and Illness, 7th Edition



MULTIPLE CHOICE

1. What is the branch of science that studies how the body functions?
 - a. Anatomy
 - b. Histology
 - c. Pathology
 - d. Physiology

ANS: D PTS: 1

2. Which word comes from the Greek word meaning “to dissect”?
 - a. Anatomy
 - b. Histology
 - c. Pathology
 - d. Physiology

ANS: A PTS: 1

3. Which of the following is a higher order of organization?
 - a. Molecule
 - b. Cell
 - c. Organ
 - d. Tissue

ANS: C PTS: 1

4. The head is located _____ to the chest.
 - a. anterior
 - b. inferior
 - c. deep
 - d. superior

ANS: D PTS: 1

5. The foot is located _____ to the leg.
 - a. proximal
 - b. superior

The Human Body in Health and Illness 7th Edition Test Bank

- c. superficial
- d. distal

ANS: D PTS: 1

6. The leg is _____ to the thigh.
- a. distal
 - b. proximal
 - c. superior
 - d. deep

ANS: A PTS: 1

7. The thigh is _____ to the foot.
- a. distal
 - b. proximal
 - c. inferior
 - d. deep

ANS: B PTS: 1

8. The thoracic cavity is _____ to the abdominopelvic cavity.
- a. deep
 - b. distal
 - c. anterior
 - d. superior

ANS: D PTS: 1

9. The kneecap is located distal to the:
- a. leg.
 - b. thigh.
 - c. foot.
 - d. toes.

ANS: B PTS: 1

10. Which organ is located in both the ventral and thoracic cavities?
- a. Stomach
 - b. Liver
 - c. Lung
 - d. Spinal cord

ANS: C PTS: 1

11. Which organ is located in the ventral cavity but not in the thoracic cavity?
- a. Lung
 - b. Heart
 - c. Liver
 - d. Brain

ANS: C PTS: 1

12. Which organ is located in the dorsal cavity?

The Human Body in Health and Illness 7th Edition Test Bank

- a. Liver
- b. Brain
- c. Heart
- d. Urinary bladder

ANS: B PTS: 1

13. Which of the following is descriptive of the location of the reproductive organs?
- a. Dorsal cavity and vertebral cavity
 - b. Mediastinum and the thoracic cavity
 - c. Ventral cavity and pelvic cavity
 - d. Pleural cavity and mediastinum

ANS: C PTS: 1

14. Which cavity is divided into quadrants?
- a. Thoracic
 - b. Abdominopelvic
 - c. Dorsal
 - d. Cranial

ANS: B PTS: 1

15. Which region is included within the right upper quadrant (RUQ)?
- a. Umbilical
 - b. Hypogastric
 - c. Right iliac
 - d. Right hypochondriac

ANS: D PTS: 1

16. Which region is included within the left lower quadrant (LLQ)?
- a. Umbilical
 - b. Left hypochondriac
 - c. Epigastric
 - d. Left iliac

ANS: D PTS: 1

17. Which of the following refers to the umbilicus?
- a. Groin
 - b. Armpit
 - c. Navel
 - d. Patellar

ANS: C PTS: 1

18. Which of the following refers to the lower back region?
- a. Groin
 - b. Axillary
 - c. Umbilical
 - d. Lumbar

ANS: D PTS: 1

The Human Body in Health and Illness 7th Edition Test Bank

19. Which of the following refers to the groin region?

- a. Axillary
- b. Lumbar
- c. Cranial
- d. Inguinal

ANS: D PTS: 1

20. Which of the following refers to the area in front of the elbow?

- a. Axillary
- b. Brachial
- c. Antecubital
- d. Popliteal

ANS: C PTS: 1

21. Which area appears only on the anterior part of the body?

- a. Popliteal
- b. Umbilical
- c. Lumbar
- d. Occipital

ANS: B PTS: 1

22. Which area appears only on the posterior part of the body?

- a. Gluteal
- b. Patellar
- c. Umbilical
- d. Sternal

ANS: A PTS: 1

23. Which area is inferior to the diaphragm?

- a. Axillary
- b. Inguinal
- c. Occipital
- d. Cervical

ANS: B PTS: 1

24. What is another name for the frontal plane?

- a. Sagittal plane
- b. Cross section
- c. Transverse plane
- d. Coronal plane

ANS: D PTS: 1

25. Which plane divides the body into right and left halves?

- a. Sagittal
- b. Coronal
- c. Transverse
- d. Frontal

The Human Body in Health and Illness 7th Edition Test Bank

ANS: A PTS: 1

26. In which cavity is the mediastinum located?

- a. Pelvic
- b. Dorsal
- c. Thoracic
- d. Abdominal

ANS: C PTS: 1

27. Which organ is located within the mediastinum?

- a. Lungs
- b. Stomach
- c. Liver
- d. Heart

ANS: D PTS: 1

28. In which cavity is the heart not located?

- a. Mediastinum
- b. Thoracic cavity
- c. Ventral cavity
- d. Dorsal cavity

ANS: D PTS: 1

29. Which organ is located in the ventral cavity and thoracic cavity but not in the mediastinum?

- a. Lung
- b. Liver
- c. Stomach
- d. Heart

ANS: A PTS: 1

30. Which group is incorrect?

- a. Planes: transverse, sagittal, frontal
- b. Cavities: dorsal, ventral
- c. Ventral cavities: thoracic, vertebral
- d. Organs: heart, stomach, lungs, brain

ANS: C PTS: 1

31. Which group is incorrect?

- a. Cavities: dorsal, ventral
- b. Ventral cavities: thoracic, abdominopelvic
- c. Organ systems: circulatory, digestive, respiratory, brain
- d. Organs: heart, stomach, lungs, liver

ANS: A PTS: 1

32. Which group is incorrect?

- a. Planes: sagittal, frontal, transverse
- b. Ventral cavities: thoracic, abdominopelvic, cranial

The Human Body in Health and Illness 7th Edition Test Bank

- c. Dorsal cavities: cranial, vertebral
- d. Organ systems: circulatory, digestive, respiratory

ANS: B PTS: 1

33. The distal humerus (arm bone) is:
- a. closer to the axillary area than to the elbow.
 - b. closer to the wrist than to the antecubital area.
 - c. distal to the wrist.
 - d. closer to the elbow than to the axillary area.

ANS: D PTS: 1

34. The proximal end of the thigh bone (femur) is:
- a. distal to the knee.
 - b. closer to the knee than to the inguinal area.
 - c. distal to the pedal area.
 - d. closer to the inguinal area than to the umbilical area.

ANS: D PTS: 1

35. The lung is located in the thoracic cavity. What is the relationship of the lung to the head?
- a. Inferior
 - b. Deep
 - c. Anterior
 - d. Superior

ANS: A PTS: 1

36. Which of the following is superior to the umbilicus?
- a. Groin
 - b. Popliteal area
 - c. Sternal area
 - d. Pelvic cavity

ANS: C PTS: 1

37. The heart is located in all the following except the:
- a. mediastinum.
 - b. ventral cavity.
 - c. cranial cavity.
 - d. thoracic cavity.

ANS: C PTS: 1

38. The lungs are located in all the following except the:
- a. thoracic cavity.
 - b. mediastinum.
 - c. ventral cavity.
 - d. pleural cavity.

ANS: B PTS: 1

39. Which of the following is true of the dorsal cavity?

The Human Body in Health and Illness 7th Edition Test Bank

- a. It contains the mediastinum.
- b. It contains the brain and spinal cord.
- c. It contains the thoracic cavity.
- d. It is smaller than the cranial cavity.

ANS: B PTS: 1

40. The sternal area is:
- a. superior to the cervical region.
 - b. the breastbone area.
 - c. deep to the mediastinum.
 - d. inferior to the thoracic cavity.

ANS: B PTS: 1

41. Which of the following is descriptive of the mediastinum?
- a. Thoracic cavity
 - b. Dorsal cavity
 - c. Abdominopelvic cavity
 - d. RUQ

ANS: A PTS: 1

42. The sagittal plane:
- a. is also called the *coronal plane*.
 - b. splits the body into a top and bottom.
 - c. splits the body into front and back.
 - d. splits the body into right and left.

ANS: D PTS: 1

43. Which of the following is least descriptive of the occipital area?
- a. Cranial
 - b. Midepigasttric
 - c. Posterior head
 - d. Superior to the cervical area

ANS: B PTS: 1

44. A patient has been in a car wreck and is admitted to the emergency department with a chief complaint of severe cervical pain accompanied by loss of sensation in all extremities. Which of the following indicates the site of pain?
- a. Lower back
 - b. Both knees
 - c. Neck
 - d. RUQ

ANS: C PTS: 1

45. The LUQ is:
- a. inferior to the sternal area.
 - b. inferior to the epigastric region.
 - c. inferior to the umbilical region.
 - d. located in the groin.

The Human Body in Health and Illness 7th Edition Test Bank

ANS: A PTS: 1

46. Which of the following describes pain that is located immediately below the shoulder blade?
- Cervical
 - Lumbar
 - Flank pain
 - Subscapular

ANS: D PTS: 1

47. Which of the following is superior to the lumbar region?
- Scapular
 - Inguinal
 - Popliteal
 - Gluteal

ANS: A PTS: 1

48. A 26-year-old man is scheduled for the surgical repair of a right inguinal hernia. Which of the following areas is involved surgically?
- RUQ
 - Umbilical region
 - Right iliac region
 - Right hypochondriac region

ANS: C PTS: 1

49. Refer to the previous question. On the first postoperative day, the patient is most likely to experience pain when he:
- brushes his teeth.
 - eats breakfast.
 - walks.
 - speaks on the phone.

ANS: C PTS: 1

50. A physician has diagnosed a patient as having an enlarged liver. According to the patient's chart, his liver is measured as being two fingers below the costal margin of the rib cage. Where was the physician palpating (feeling) to get this measurement?
- Umbilical region
 - LUQ
 - Hypogastric region
 - RUQ

ANS: D PTS: 1

51. A patient was admitted to the emergency department and the physician recorded the patient's pain as being substernal, radiating to the left axillary region. Which of the following is a restatement of this description?
- The pain is sharp and is associated with nausea and vomiting.
 - The pain is indicative of an inguinal hernia.
 - The pain begins in the chest and radiates to the left flank and medial thigh.
 - The pain originates behind the breastbone and radiates to the left armpit area.

The Human Body in Health and Illness 7th Edition Test Bank

ANS: D PTS: 1

52. A patient with a history of gallbladder disease complains of midepigastriic pain that radiates to the right subscapular region. Which of the following best describes the pain?
- High abdominal pain that radiates to the groin
 - Crushing chest pain
 - Aching pain behind the breastbone, radiating to the left shoulder
 - High abdominal pain, radiating to below the right shoulder blade area

ANS: D PTS: 1

53. Which plane preserves an upper and lower half of the body?
- Transverse plane
 - Coronal plane
 - Frontal plane
 - Midsagittal

ANS: A PTS: 1

54. Which of the following is contained in the ventral cavity?
- Thoracic cavity
 - Pleural cavities
 - Abdominopelvic cavity
 - All are correct

ANS: D PTS: 1

55. Which of the following is true?
- The wrist is proximal to the elbow.
 - The distal humerus (arm bone) is closer to the axilla than to the elbow.
 - The proximal thigh bone is closer to the hip than to the knee.
 - The distal tibia (shin bone) is closer to the knee than to the ankle.

ANS: C PTS: 1

56. Which of the following is true?
- The distal thigh bone (femur) is closer to the hip than to the knee.
 - The distal humerus (arm bone) is closer to the axilla than to the elbow.
 - The distal shin bone (tibia) is closer to the ankle than to the knee.
 - The lateral thigh is closer to the midline of the body than is the medial thigh.

ANS: C PTS: 1

57. The medial thigh is located:
- along the plantar surface of the foot.
 - along the inner surface of the upper extremity.
 - on the inner thigh region.
 - distal to the popliteal region.

ANS: C PTS: 1

58. Which term refers to “beneath the ribs”?
- Iliac

The Human Body in Health and Illness 7th Edition Test Bank

- b. Inguinal
- c. Hypochondriac
- d. RLQ

ANS: C PTS: 1

59. The term *viscera* refers to:
- a. the organs of the body.
 - b. the cavities contained within the ventral cavity.
 - c. the cavities contained within the thoracic cavity.
 - d. the divisions of the abdominopelvic cavity.

ANS: A PTS: 1

60. The ventral cavity is the anterior cavity; the _____ is the posterior cavity.
- a. thoracic cavity
 - b. dorsal cavity
 - c. pleural cavity
 - d. mediastinum

ANS: B PTS: 1

61. The caudal part of the spinal cord is:
- a. superior to the thoracic part of the spinal cord.
 - b. located near the tailbone.
 - c. interior to the cervical spinal cord.
 - d. located near the brain.

ANS: B PTS: 1

62. Which of the following includes the right iliac region?
- a. RUQ
 - b. Epigastric region
 - c. Umbilical region
 - d. RLQ

ANS: D PTS: 1

63. The medial canthus (corner) of the eye is:
- a. located near the nose.
 - b. located near the ear.
 - c. superior to the eyebrow.
 - d. inferior to the eyelid.

ANS: A PTS: 1

64. The plantar region is:
- a. located in the upper extremities.
 - b. the bottom of the foot.
 - c. proximal to the knee.
 - d. the groin.

ANS: B PTS: 1